

Tension band fixation

Christof A Müller

Learning outcomes

At the end of this lecture you will be able to:

- Explain the principle of tension band fixation
- List indications for tension band fixation
- Describe step-by-step the two most commonly used techniques
- Discuss possible complications

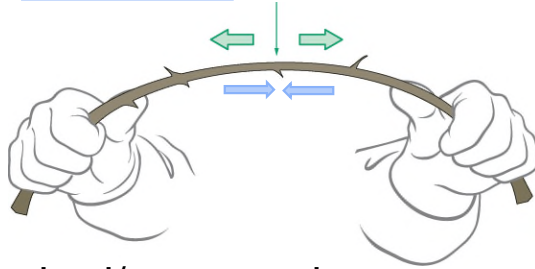
AO

At the end of this lecture you will be able to:

- Explain the principle of tension band wiring
- Sum up the indications for tension band wiring
- Describe step-by-step the two most commonly used techniques
- Discuss possible complications that might occur.

What does «tension band principle» mean?

- Bending force applied eccentrically
 - Causes tension and compression within a column (bone)

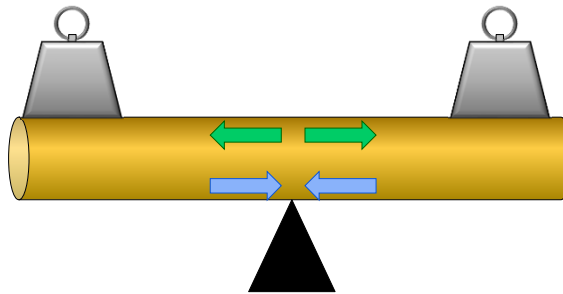


- Tension can be absorbed/converted
 - By a band (wire, plate) on the tension side
 - However opposite side of column (bone) must be able to resist compression

AO

Eccentric overloading of a beam/bone

- What will happen?



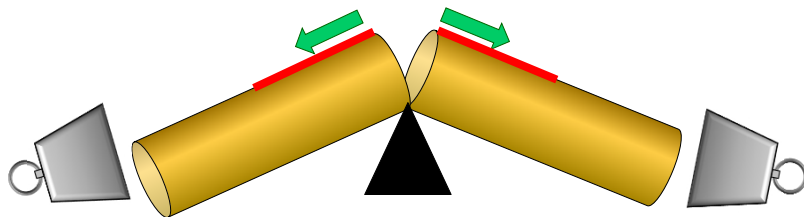
AO

Here we see an eccentric loaded column
What will happen?

Image courtesy: Prof. Chris Colton.

Eccentric overloading of a beam/bone

- Will break:
 - One side loaded in tension
 - Opposite side loaded in compression



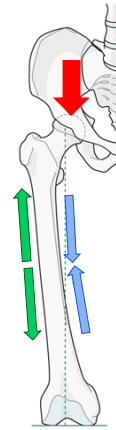
AO

This example explains the borrowed principle of Pauwels, an engineer (1935) who stated what happens when a beam or a bone is overloaded eccentrically. The beam at the level of the fulcrum (pivot) will break. The fracture will start at the upper tension surface (red) of the beam. The fracture then completes across the bone until the compression side breaks.

Image courtesy: Prof. Chris Colton.

Eccentric loading of the femur

- Fracture will occur if overloaded

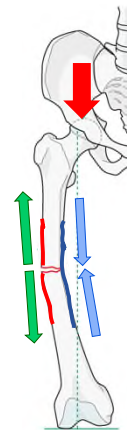


AO

Because of the bowed shape of the femur, a vertical load passing down the load axis (from the centre of the femoral head to the intercondylar notch), will result in eccentric loading, with the lateral cortex under tension and the medial cortex in compression

Eccentric loading of the femur

- Fracture will occur if overloaded
 - On tension side
 - Opposite side loaded in compression

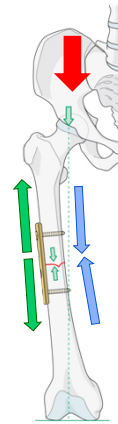


AO

Overload will result in failure in tension of the lateral cortex and propagation of the fracture through to the medial cortex

Application of tension band

- Lateral plate functions as “tension band”
 - Tension is absorbed by the plate
 - The compression cortex becomes stable

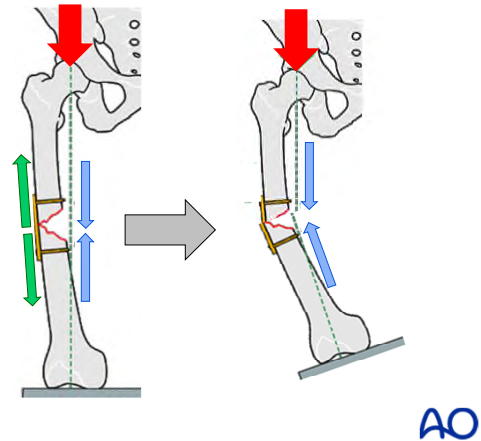


AO

If a device (here a plate) is applied to the tension side of the bone, so that opening cannot occur, the load becomes a compressive one over the whole width of the bone.

Application of tension band


- Plate functions as “tension band”
 - If opposite cortex is intact
 - If the compression cortex is defective, the tension band cannot resist bending



If a tension band is applied to the tension cortex, but the opposite cortex is defective and cannot resist compression, then the fixation will fail under axial load

Principle of «tension band» means:

- To induce interfragmentary compression on a bending fracture
 - The “tension band” may be an implant (wire, plate)
 - Applied on the “tension side” of a bone
 - Making use of the functional movement of the limb
 - Tension forces are converted into compression forces, provided the compression cortex is not deficient

Tension forces ^{„Tension band“}  Compression forces

AO

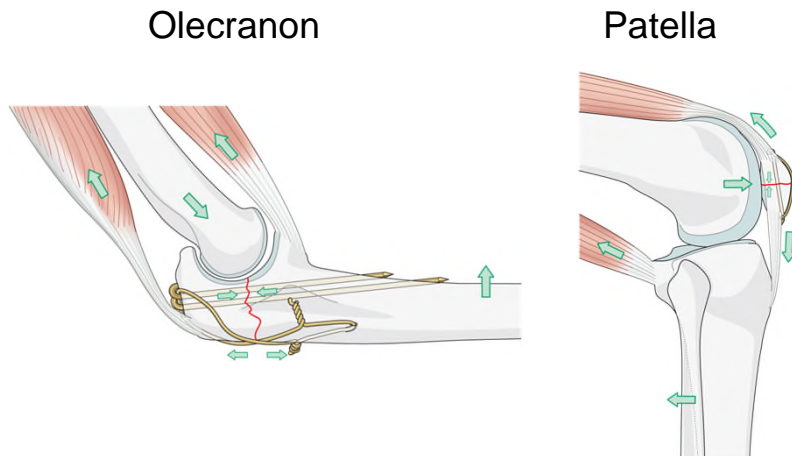
Indications for tension band wiring

- Eccentrically loaded articular fractures, which need:
 - Absolute stability (by interfragmentary compression)
 - Leading to direct bone healing

AO

Tension band wiring is a fixation technique which results in absolute stability. Interfragmentary compression and direct bone healing is obtained. Other fixation methods leading where absolute stability is achieved are fixations with lag screw and fixation with plate and screws.

Most common indications

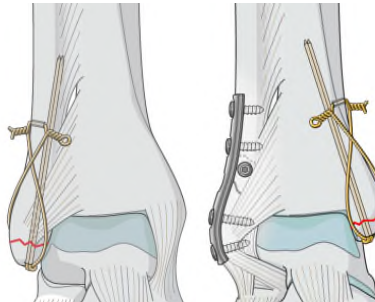
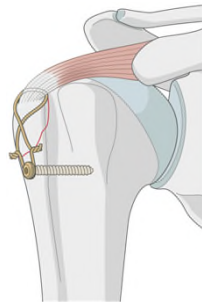


AO

Wires are use as tension band most commonly in patella, and olecranon.

Other indications

- Tuberosity of the humerus
- Lateral and medial malleoli
- Trochanter of the femur



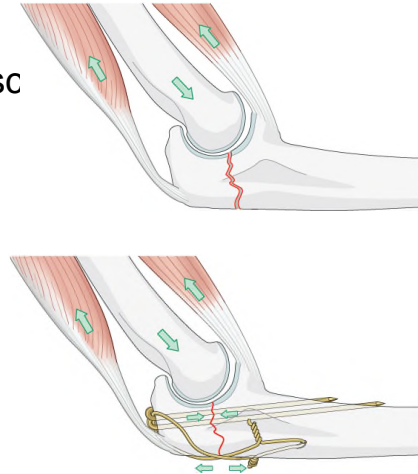
AO

Indications—Olecranon

- Pressure of condyle
- Tension of triceps and brachialis musc
- Figure of eight tension band wire



- Provide resistance to opening
 - At posterior cortex
- Induce compression
 - Across fracture site



AO

Biomechanically the olecranon is an inverted seesaw, with the distal humerus acting as the pivot while triceps and brachialis muscles pull on each side of the proximal ulna. The dorsal surface of the olecranon is therefore under tension and the ventral surface under compression.

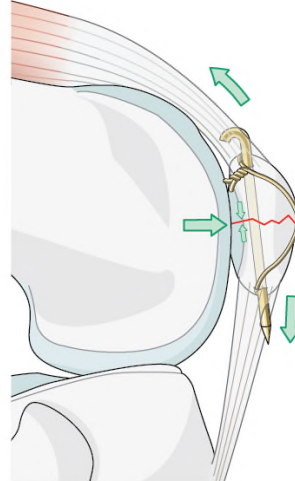
The figure of eight wire prevents opening of the posterior (tension) cortex and the forces of the triceps and brachialis then result in compression across the whole fracture plane

Indications—Patella

- Compression of condyles
- Pull of quadriceps and patellar tend
- Figure of eight wire



- Provide resistance to opening
 - At posterior cortex
- Induce compression
 - Across fracture site

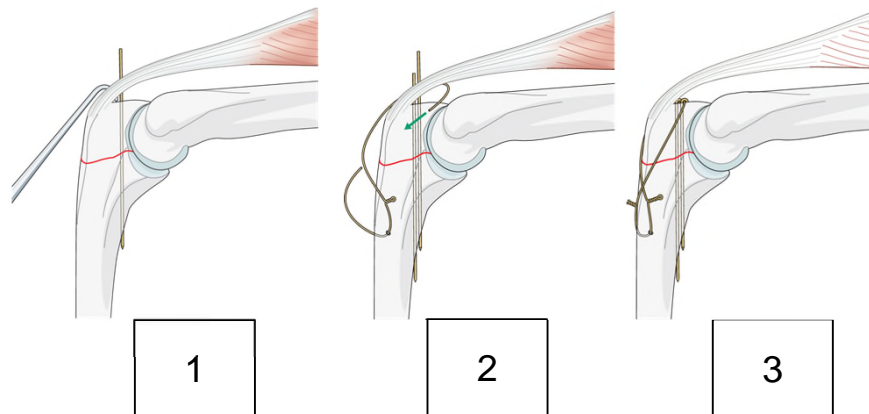


AO

Cerclage wire and the compression of condyles as well as the tension of quadriceps and patellar tendon induce resistance and compression on fracture site.

The insertion of the quadriceps and patellar tendons onto the superficial surface of the patella which provides the load and the femoral condyles which act as pivot, setting up tension at the superficial and compression at the deep surface of the patella. Failure usually occurs in tension, usually caused by a fall on the front of the knee.

Technique—Olecranon fracture



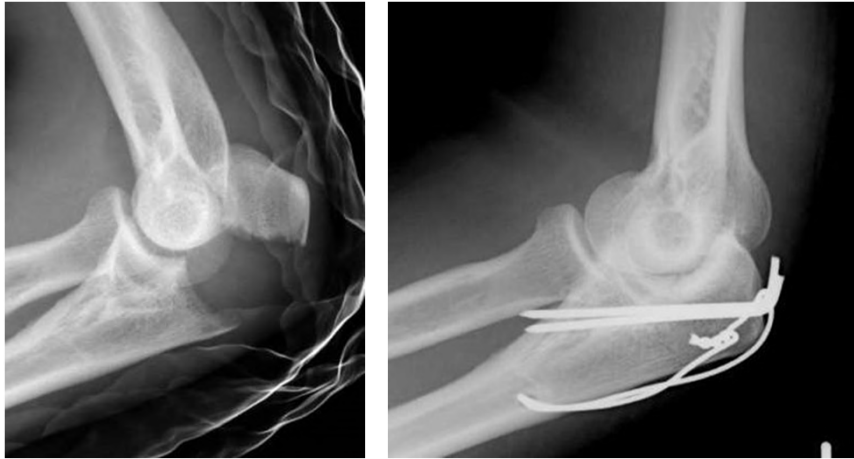AO

A simple transverse fracture can be held accurately by:

- 1) Inserting a K-wire through the fracture line.
- 2) Inserting a second K-wire parallel to the first one to prevent fragment rotation.
- 3) The tension band is provided by a figure-of-eight looped wire over the tension surface, anchored around the K-wire ends proximally, and a transverse hole through the ulna distally. The wire is tightened equally on both sides by twisting to apply compression.

Once fixed, any pull on the triceps muscle increases the dynamic compression across the fracture site.

Clinical example—Olecranon

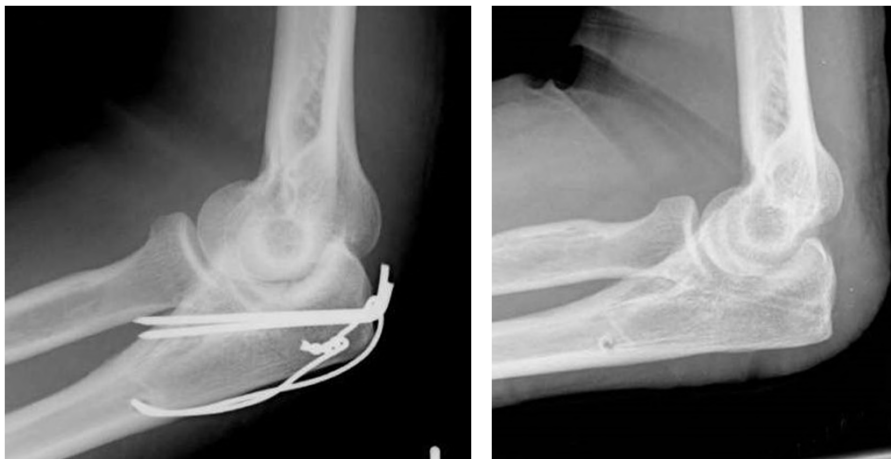

AO

This olecranon fracture has been widely separated by the pull of the triceps. The tension band wire holds the reduction and prevents the posterior cortex from opening.

The pull of the triceps and brachialis muscles is thereby converted into a compression force.

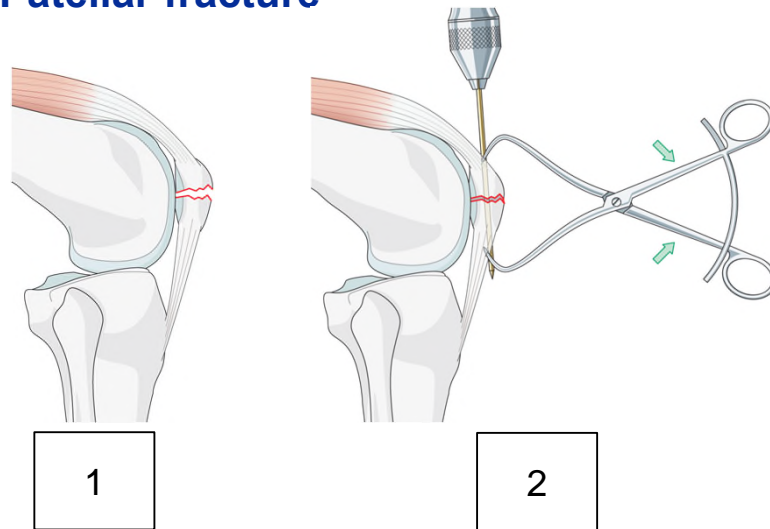
Clinical example—Olecranon



AO

The fracture healed perfectly (the implants have been removed).

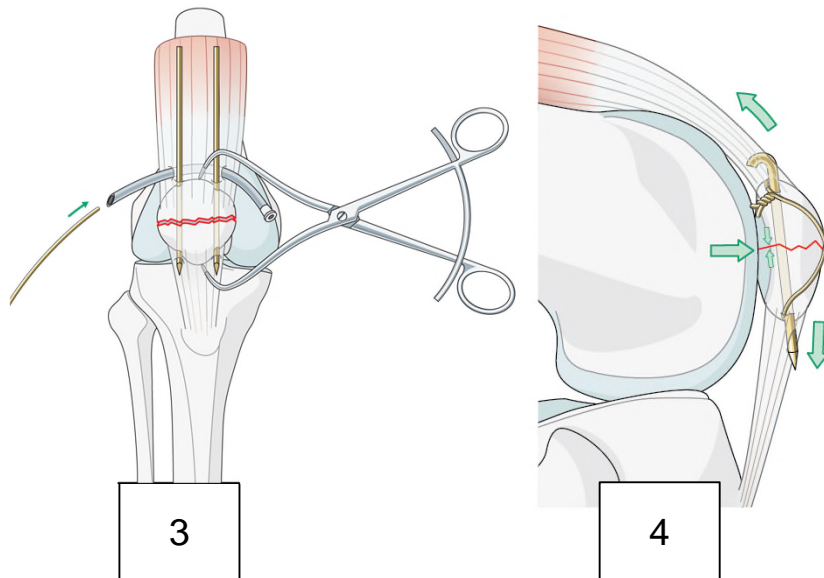
Technique—Patellar fracture



AO

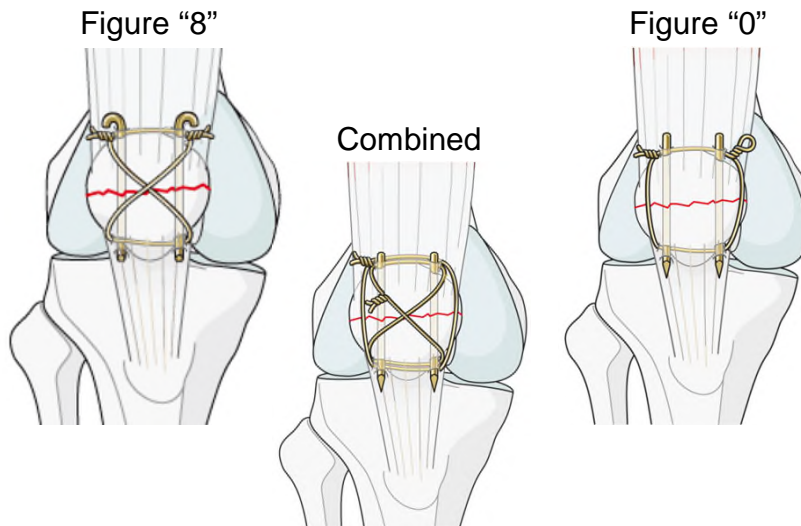
- 1) Provided the fracture is a simple transverse fracture and there is no fragmentation of the deep articular cortex.
- 2) It can be reduced with pointed forceps and held with two parallel K-wires.

Technique—Patellar fracture



3) A wire, inserted around the ends of these wires (deep to the quadriceps tendon), crossed over the front of the patella, then around the lower ends of the K wires, is tightened to provide compression. This achieved by tightening a loop on each limb of the wire.

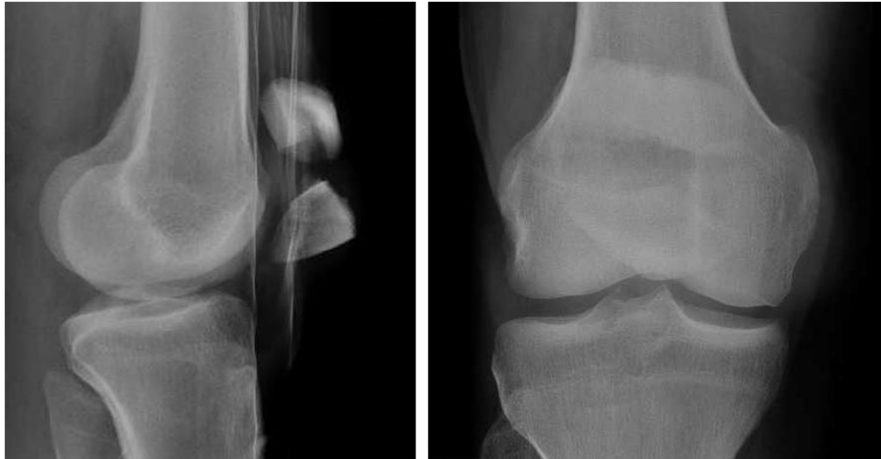
Technique—Patellar fracture



4. The pull of the quadriceps then increases dynamic compression across the fracture as the knee flexes and extends.

There are 2 options of cerclage wire technique: figure of 8 or 0. Or they may be combined (8 and 0).

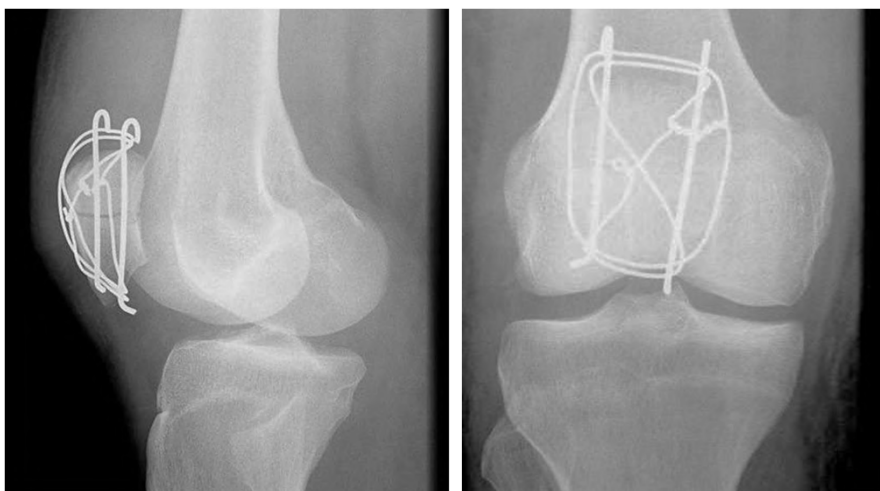Clinical example—Patella



AO

Here you can see a transverse patellar fracture, distracted by pull of quadriceps muscle.

Clinical example—Patella



AO

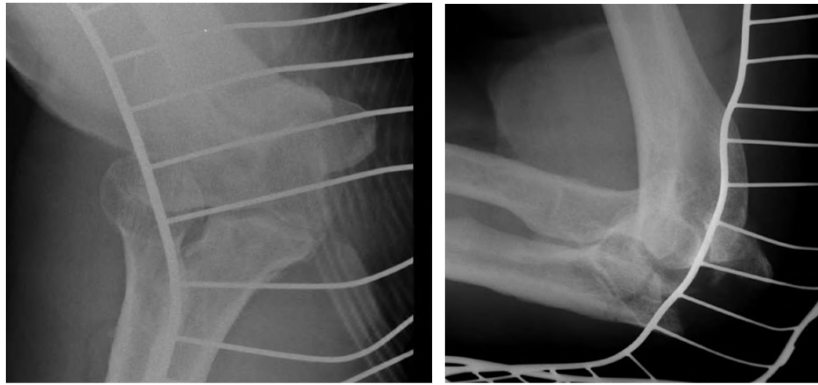
This has been reduced and stabilized with a combination figure-of-8 and O-wiring.

Complications

- Implant failure
 - Due to wrong indication
 - Osteoporosis
 - Implant loosening relatively common, early removal required
- Joint stiffness
 - Deficit in flexion and extension
 - Strong capsule and ligaments, due to the injury

AO

Case 1

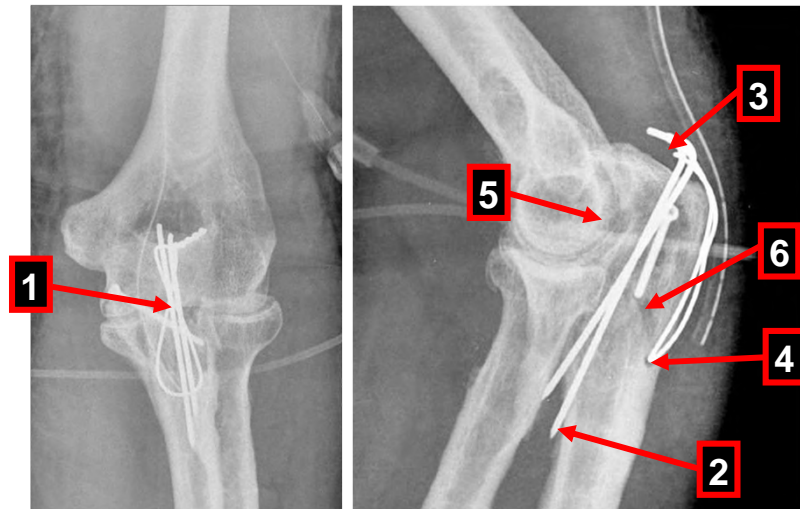


1. What about the image quality?
2. How would you classify or describe this fracture?
3. What is your suggestion for treatment?

AO

1. Unacceptable quality, no straight projection, no projection in a 90° angle.
2. Therefore classification and description of the fracture is not possible.
3. Because of lac of information, a suggestion for treatment is not possible. New images are necessary. If this is not possible a CT scan should be ordered.

Case 1



1. What about this surgical treatment?

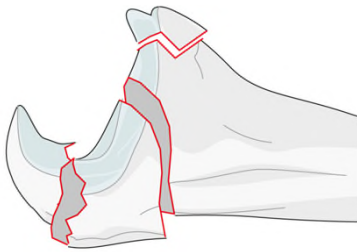
AO

1. The K-wires are too narrow. There is no rotation stability.
2. The K-wires are too long.
3. The K-wires are not fully inserted therefore the fracture is unstable.
4. The hole for the cerclage wire is too close to the fracture gap. Danger of dislocation exists.
5. There is insufficient reduction of intraarticular fracture. A fracture gap is still visible.
6. Also here there is insufficient reduction. The main fracture gap is too big.

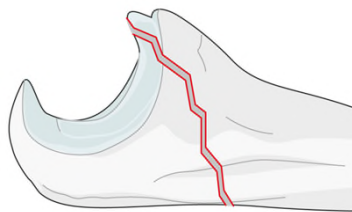
Displaced olecranon—complex fractures

- Requires tension band plate
 - Options
 - One-third tubular plate
 - Reconstruction plate
 - Locking plate

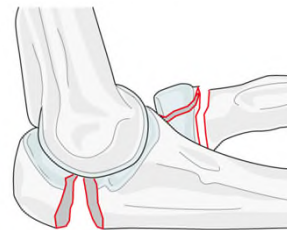
Comminuted



Oblique distal

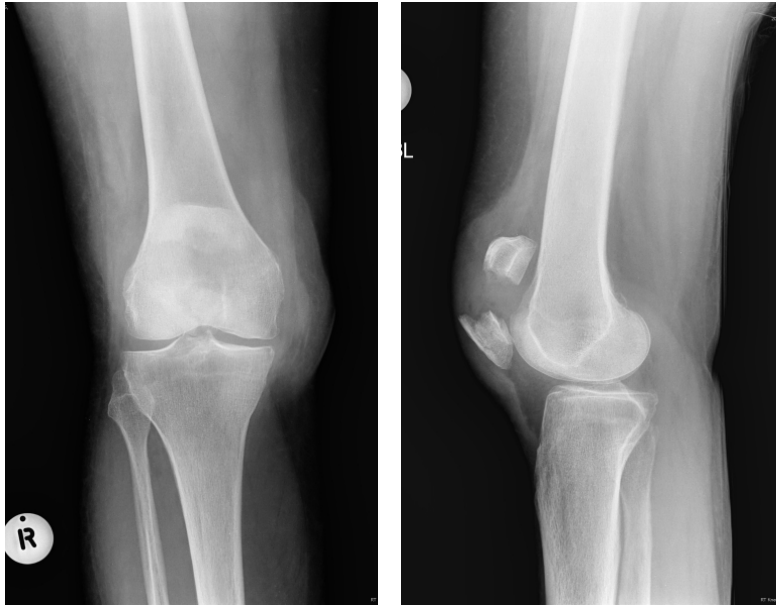

Fracture dislocation



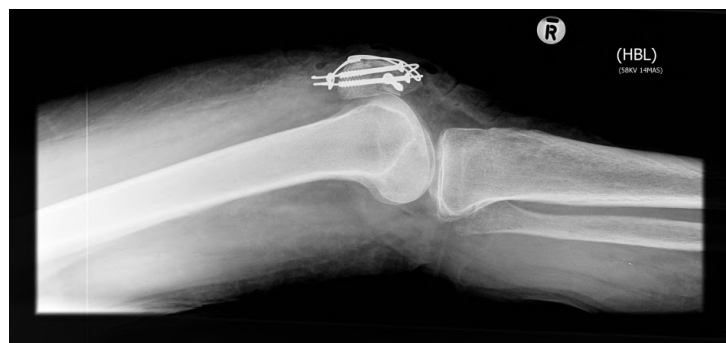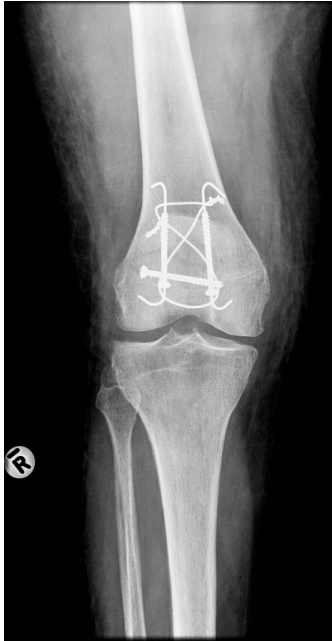AO

Displaced patellar fractures—multifragmentary (stellate)



AO

Displaced patellar fractures—multifragmentary (stellate)

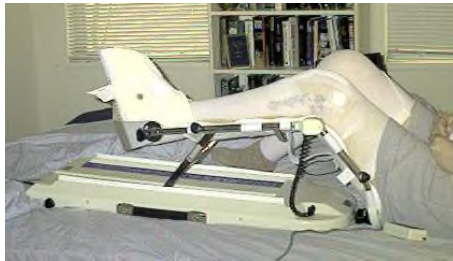

AO

Alternative fixation with cannulated screws and associated tension band applied through screws.

Aftercare

- Start functional active assisted motion early
 - Depending on fracture stability
- Motion of joint encourages interfragmentary compression
 - Active and passive



AO

Tension band wiring is an optimal mechanical principle for early functional motion.

Motion will increase the interfragmentary compression.

Questions

AO

Optional
Insert questions to check learning

Tension band wiring technique is...

1. ... always applied on the tension side of a bone
2. ...always applied on the compression side of a bone
3. ...always refers to 2 K wires and 1 cerclage wire

AO

Optional
Insert questions to check learning

Tension band wiring technique is...

1. ... always applied on the tension side of a bone



2. ...always applied on the compression side of a bone

3. ...always refers to 2 K wires and 1 cerclage wire

AO

Optional
Insert questions to check learning

Tension band wiring is a technique of...

1. ...relative stability with indirect bone healing

2. ...relative stability with direct bone healing

3. ...absolute stability with direct bone healing

AO

Optional
Insert questions to check learning

Tension band wiring is a technique of...

1. ...relative stability with indirect bone healing

2. ...relative stability with direct bone healing

3. ...absolute stability with direct bone healing



AO

Optional
Insert questions to check learning

For which anatomical regions is tension band mostly used?

1. Femoral shaft, tibial shaft, and patella

2. Patella, olecranon, and malleolus


3. Patella, olecranon, and clavicle

AO

Optional
Insert questions to check learning

For which anatomical regions is tension band mostly used?

1. Femoral shaft, tibial shaft, and patella

2. Patella, olecranon, and malleolus 

3. Patella, olecranon, and clavicle

AO

Optional
Insert questions to check learning

Summary

You should now be able to:

- Explain the principle of tension band wiring
- Sum up the indications for tension band wiring
- Describe step-by-step the two most used techniques
- Discuss possible complications that might occur

AO

You should now be able to:

- Explain the principle of tension band wiring
- Sum up the indications for tension band wiring
- Describe step-by-step the two most commonly used techniques
- Discuss possible complications that might occur.