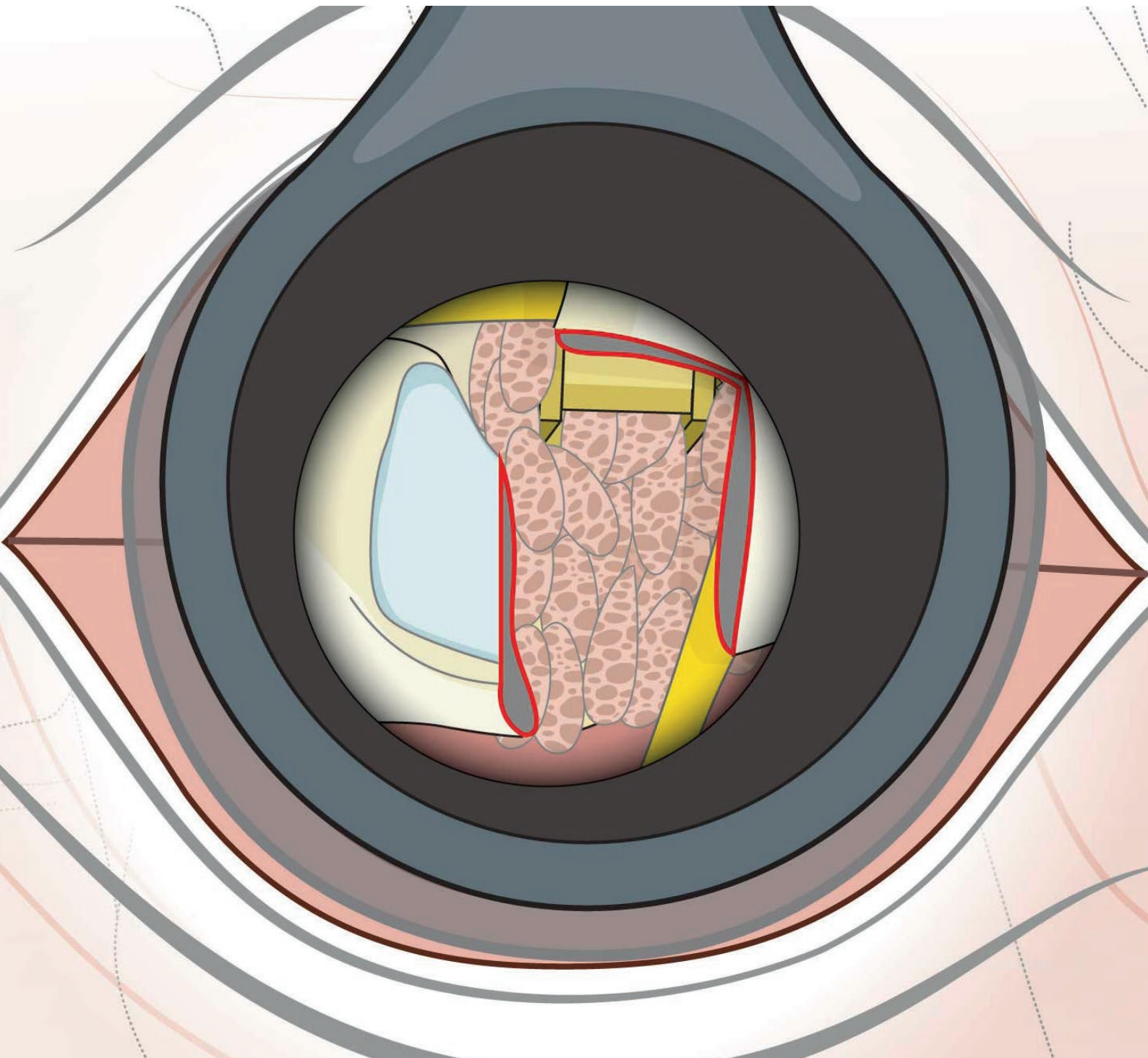


Education

Step-by-Step Guide: Key Steps in a MIS TLIF Procedure

Prepared by: Drs Roger Härtl and Daniel Gelb

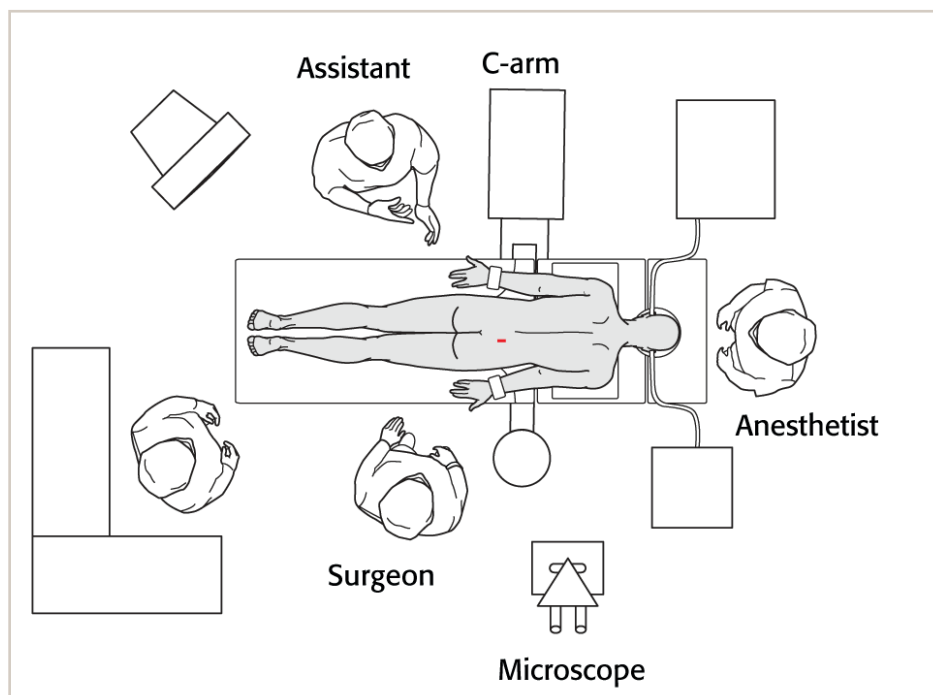


Step-by-Step Guide: Key Steps in a MIS TLIF Procedure

Prepared by Drs Roger Härtl and Daniel Gelb

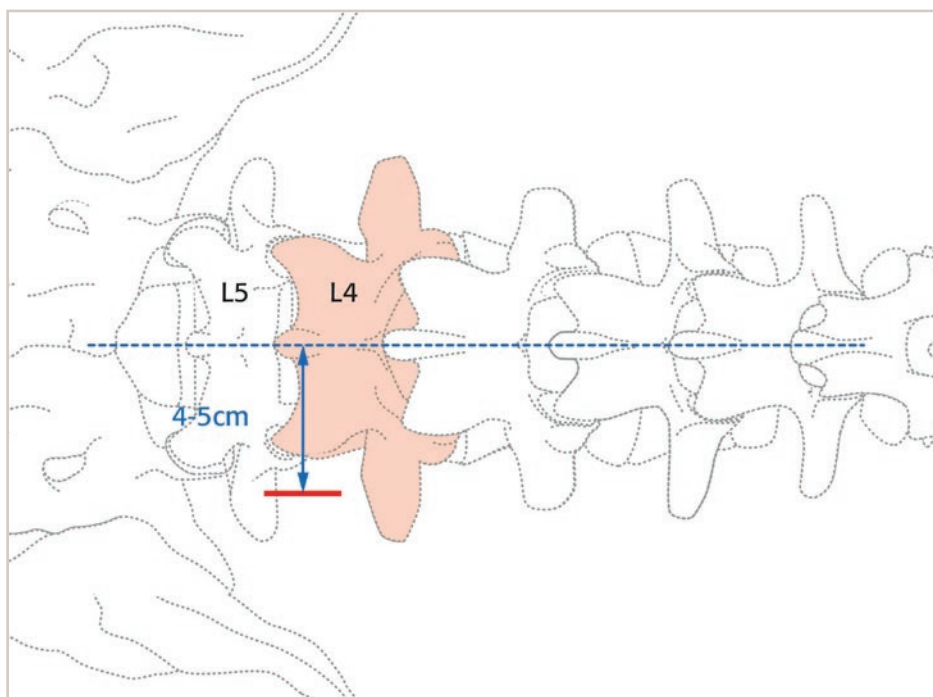
1. OR setup

In the typical OR setup for a MIS TLIF, the surgeon stands on the side of the TLIF (usually the more symptomatic side). The image intensifier is draped into the field with the screen easily visible to the surgeon.



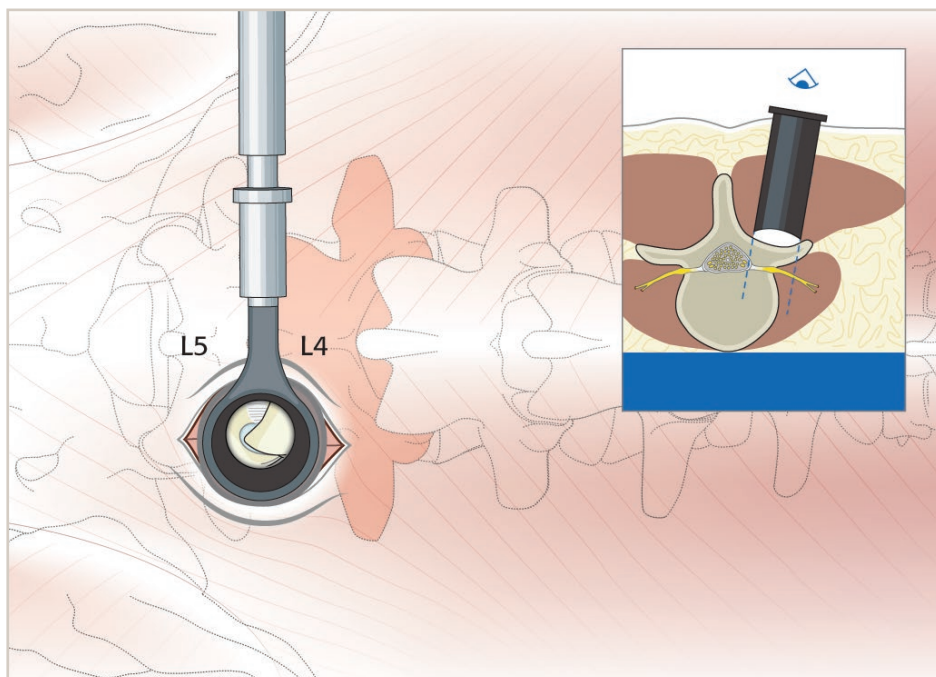
2. Incision

The incision is made at the level of the facet joint to be resected/fused. The incision is made 4 to 5 cm from the midline to allow the surgeon to work obliquely into the spinal canal from outside the pars and to easily place pedicle screws. The distance from the midline is related to the size of the patient.



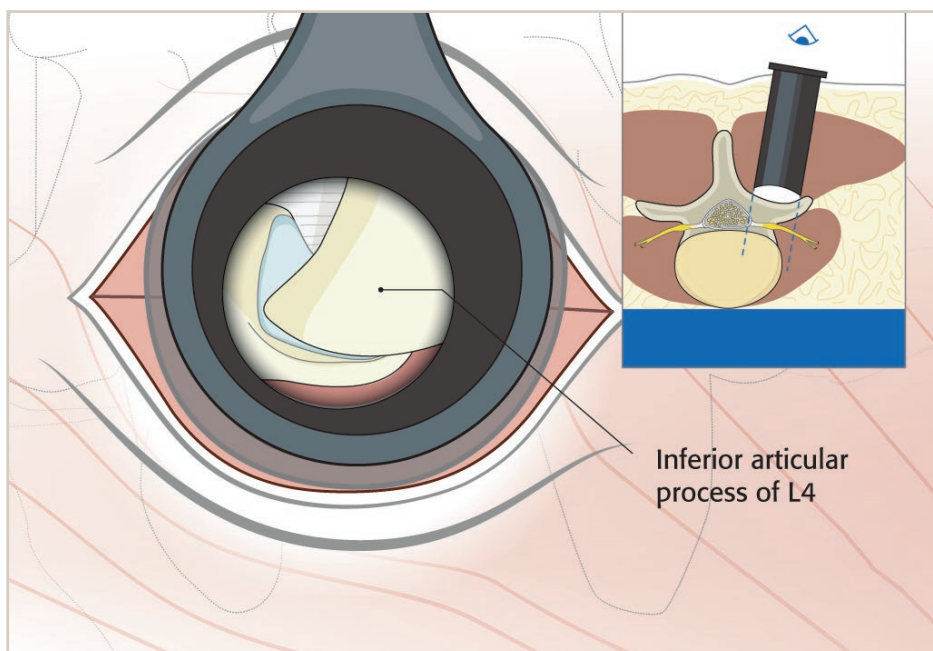
3. Soft tissue dissection

The soft tissue is bluntly dissected with sequential dilators and a table-mounted tubular retractor inserted to visualize the facet joint complex.

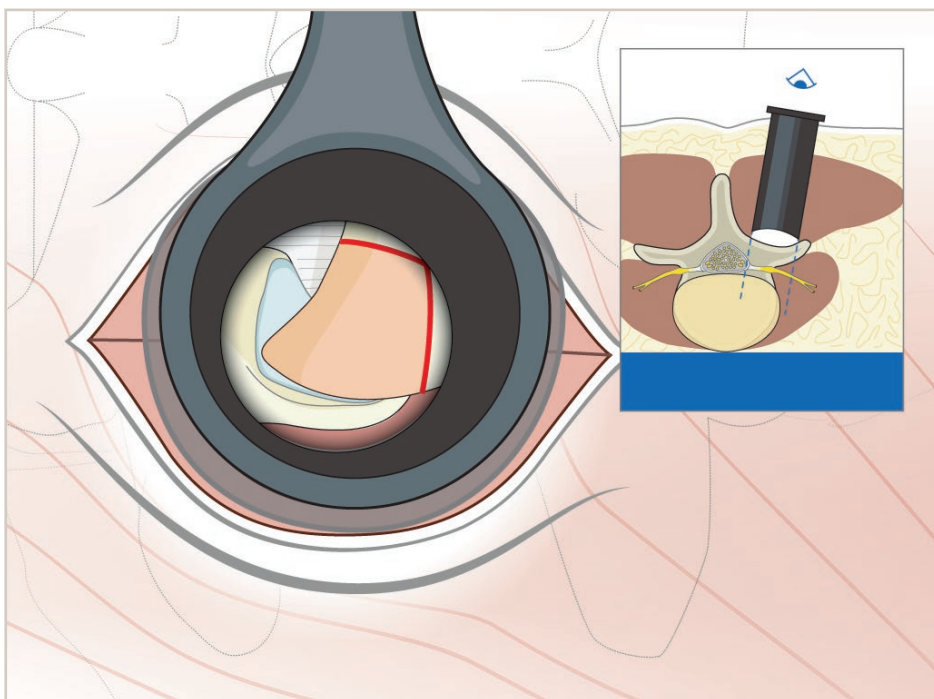


4. Visualization

Microscopic visualization gives excellent magnification and illumination. This allows identification of the inferior articulating facet.

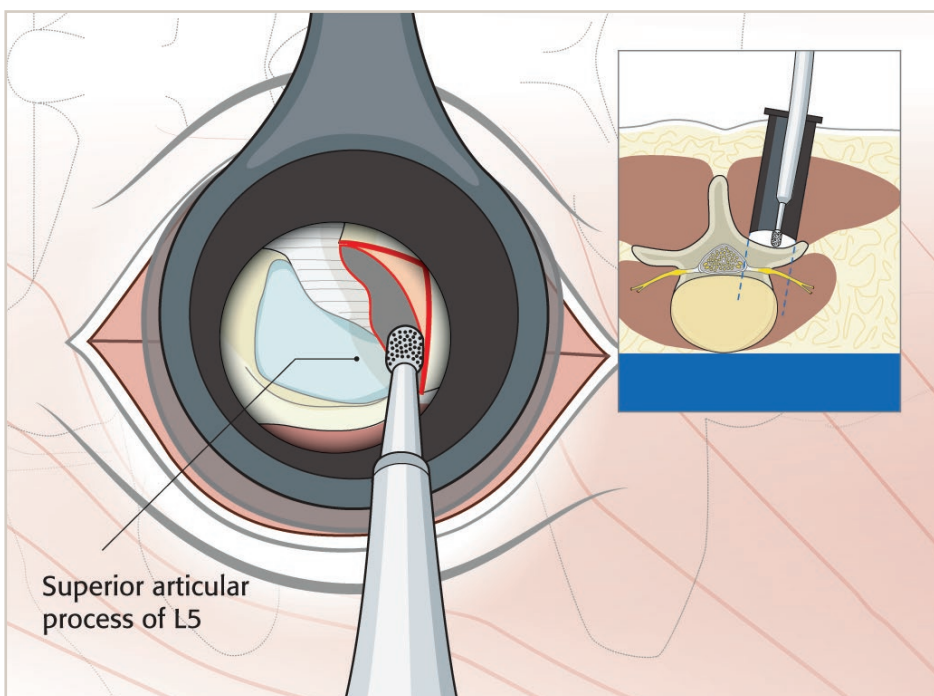


5. The facet capsule is opened



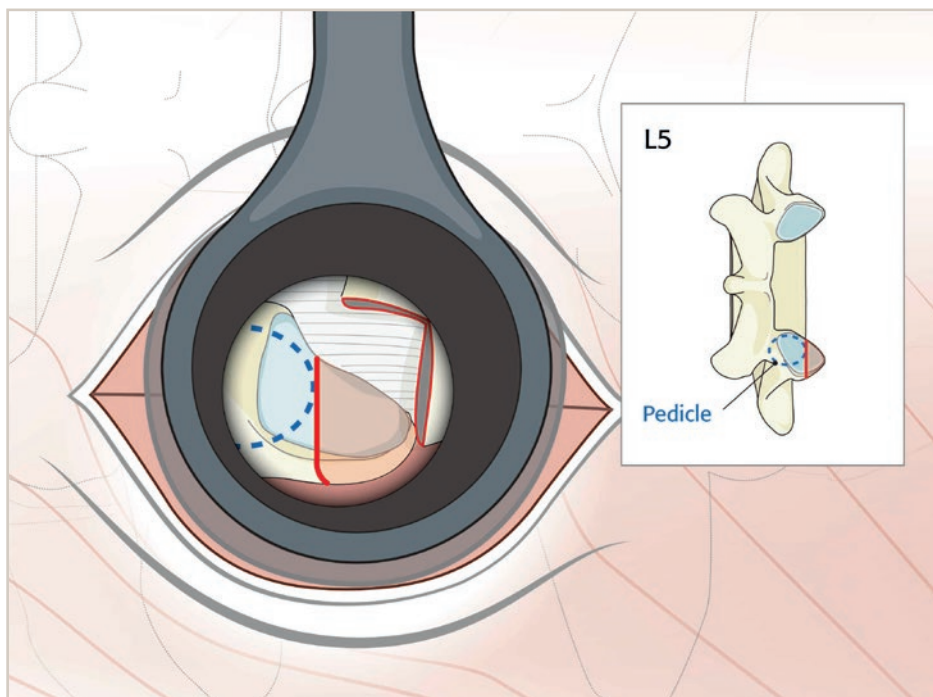
6. Resection of inferior facet

Using a high-speed burr, the inferior facet is resected.



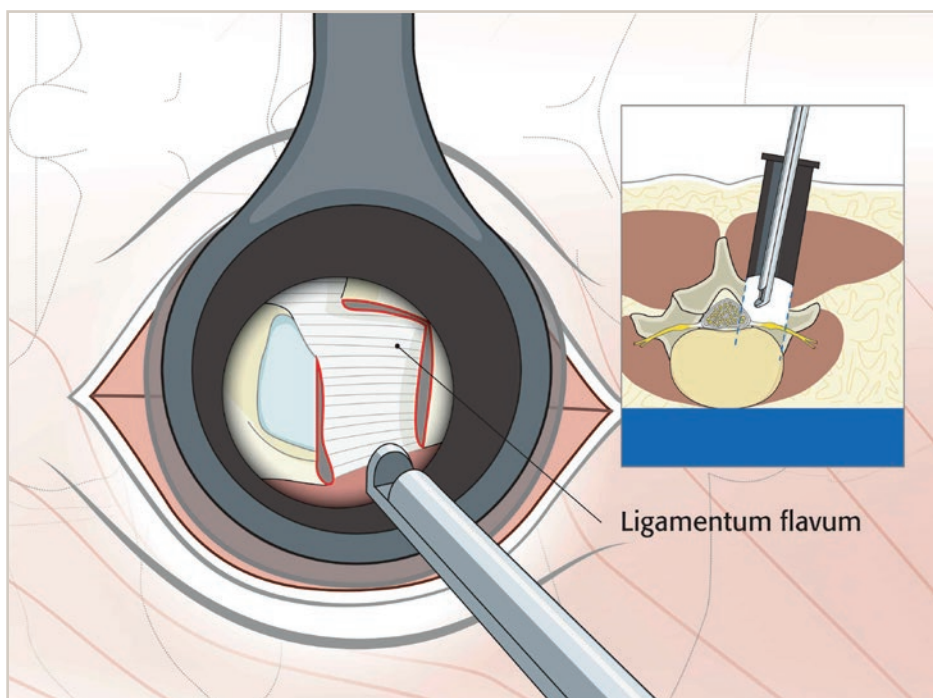
7. Resection of superior facet

The superior facet is resected from its tip down to the superior border of the pedicle.



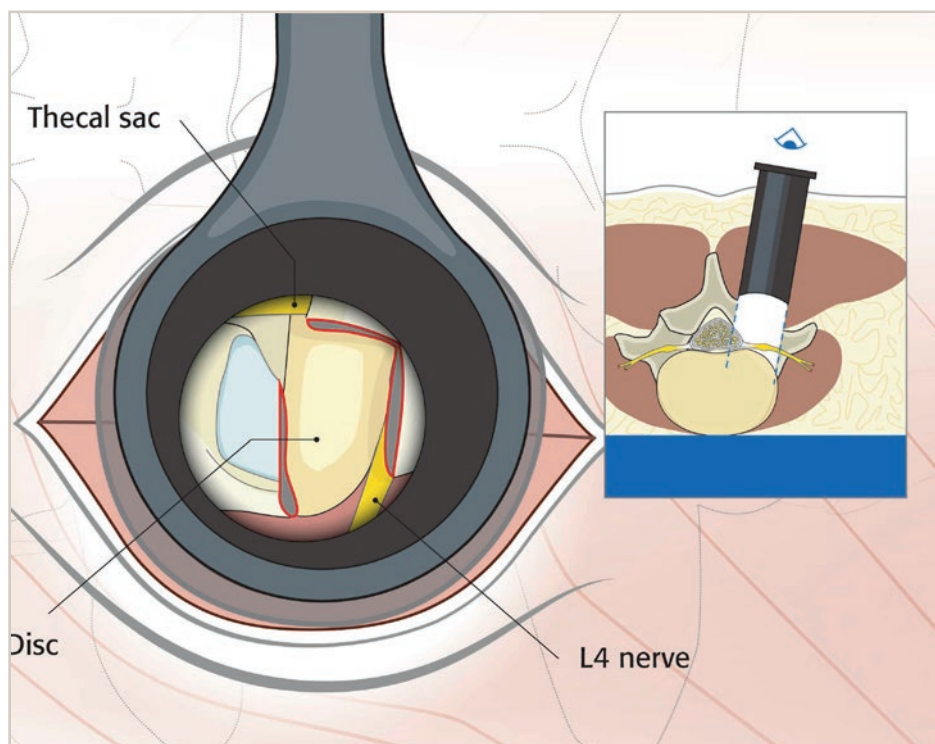
8. Resection of the ligamentum flavum

The ligamentum flavum can now be resected from lateral to medial to expose the disc within the foramen.



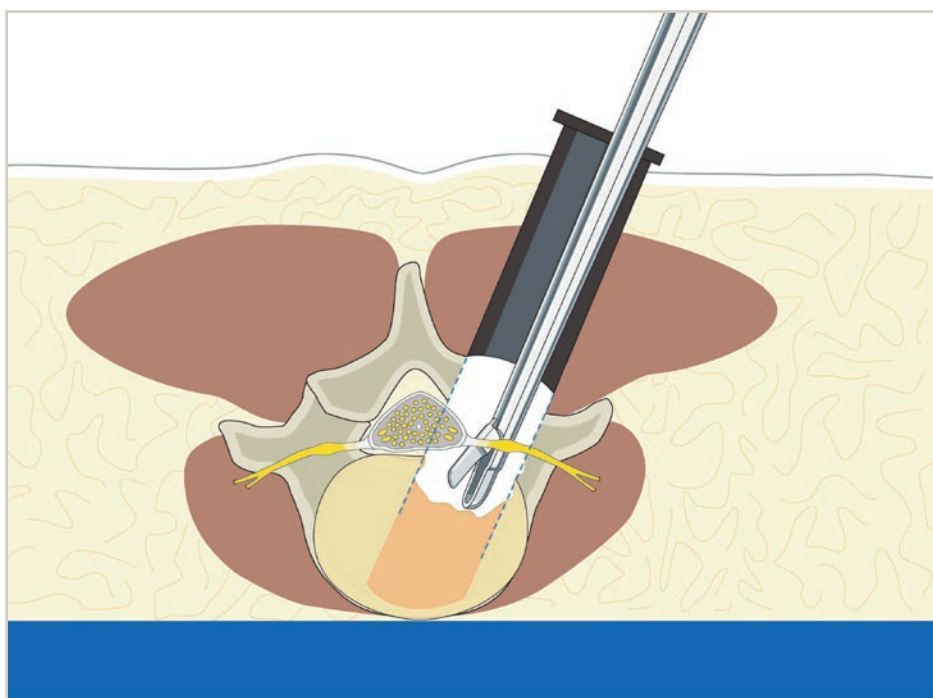
9. Visualization of the disc

Following removal of the ligamentum flavum, the disc will be seen in the floor of the spinal canal. The exiting nerve root passes under the remaining pars interarticularis at the superior margin of the field.



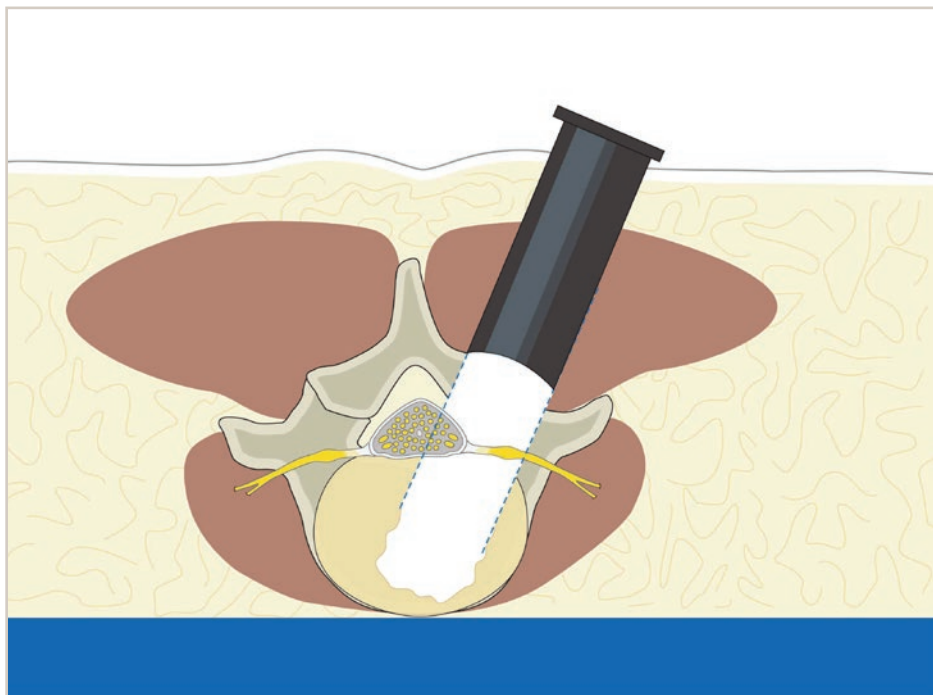
10. Discectomy

A thorough discectomy is then performed. Cartilage from the vertebral endplates is completely removed to expose the bony endplates.



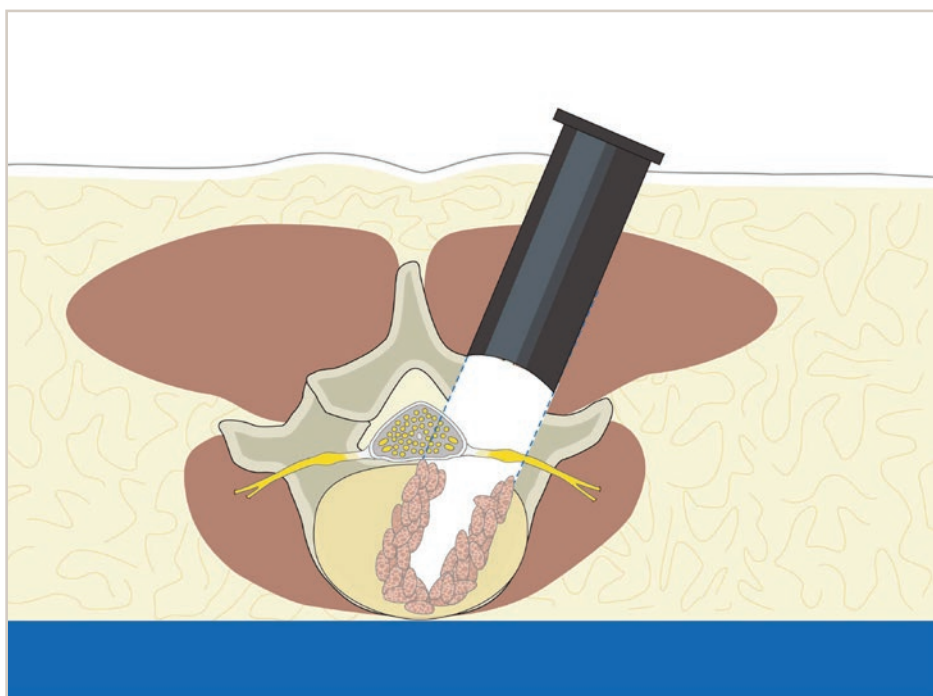
11. Discectomy space

The discectomy space is visualized.



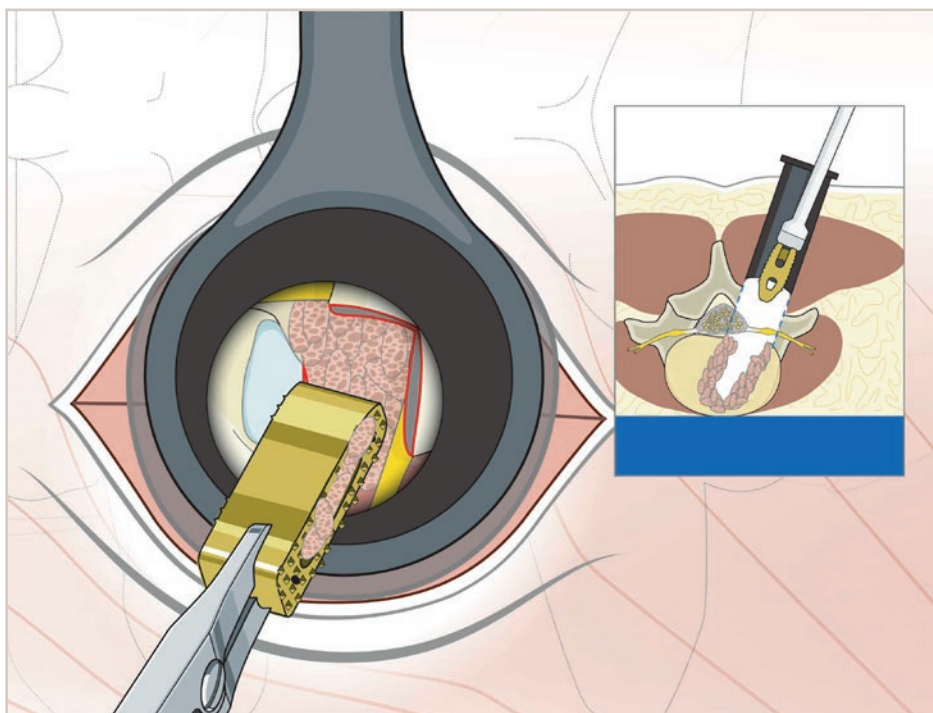
12. Bone graft

Morselized bone graft is packed into the anterior portion of the discectomy space.



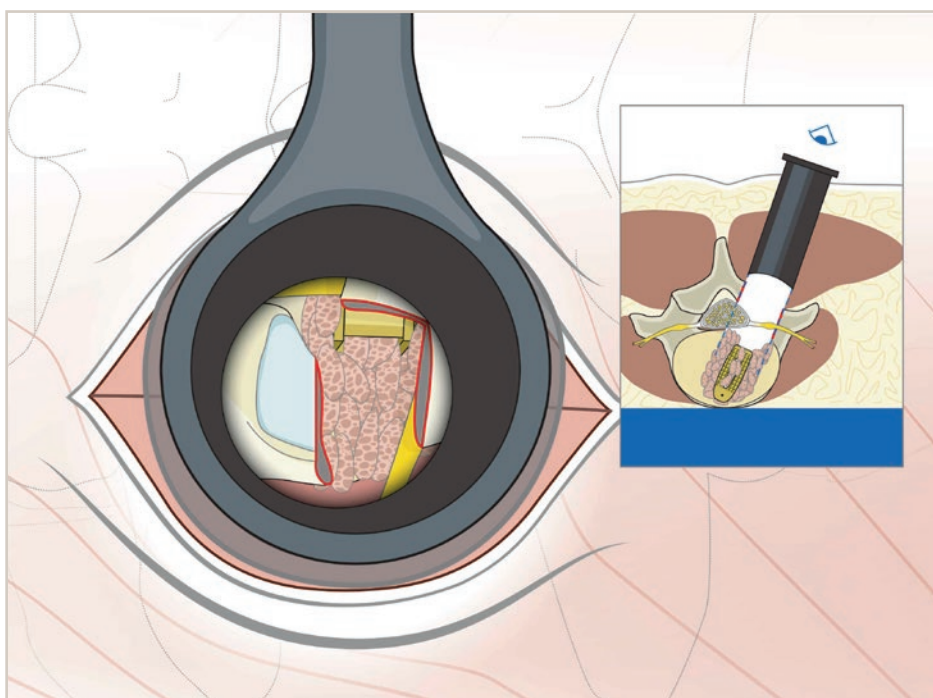
13. Structural implant (with bone graft)

A structural implant of appropriate size, filled with additional bone graft, is impacted into the discectomy space.



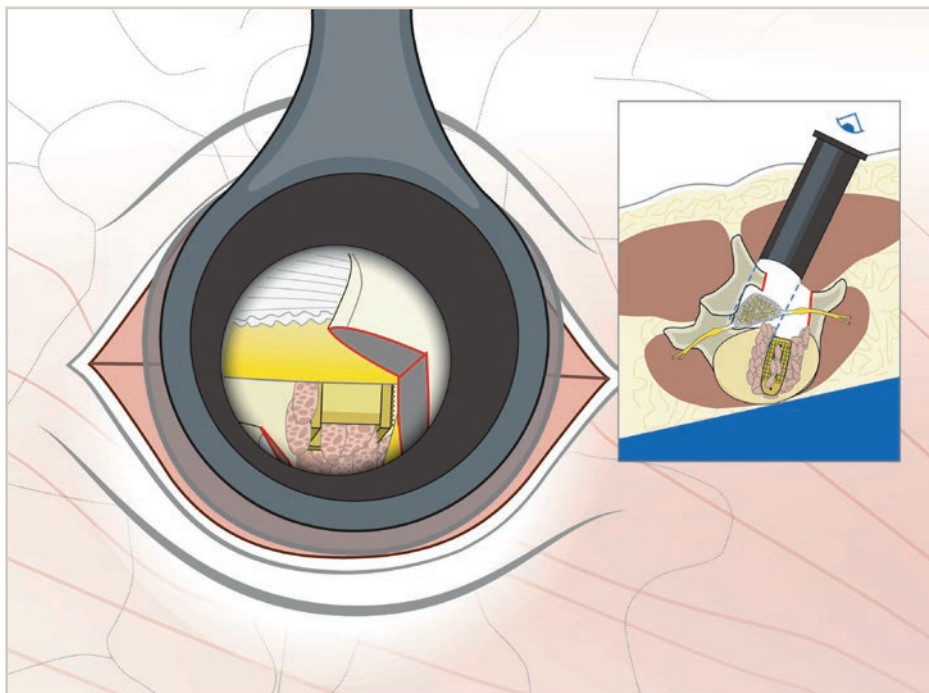
14. Disc space filled with implant and bone graft

This illustrates the typical appearance of the intervertebral disc space filled with the implant and abundant bone graft.



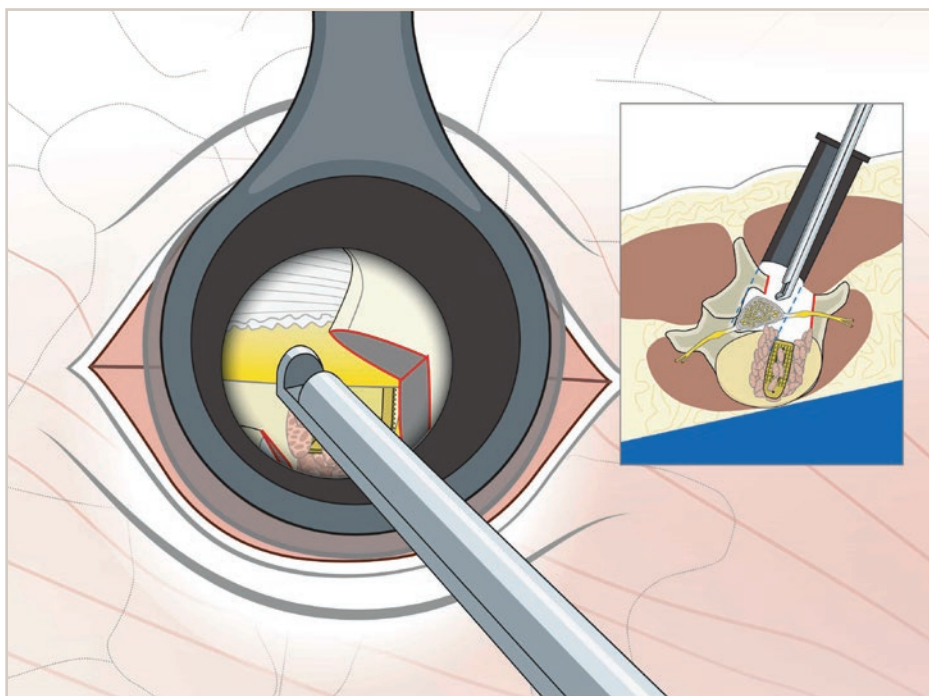
15. Complete insertion of implant into disc space

Rotation of the operative table away from the surgeon allows for more medial visualization to ensure that the traversing nerve root is completely decompressed. The implant is inserted completely into the disc space.



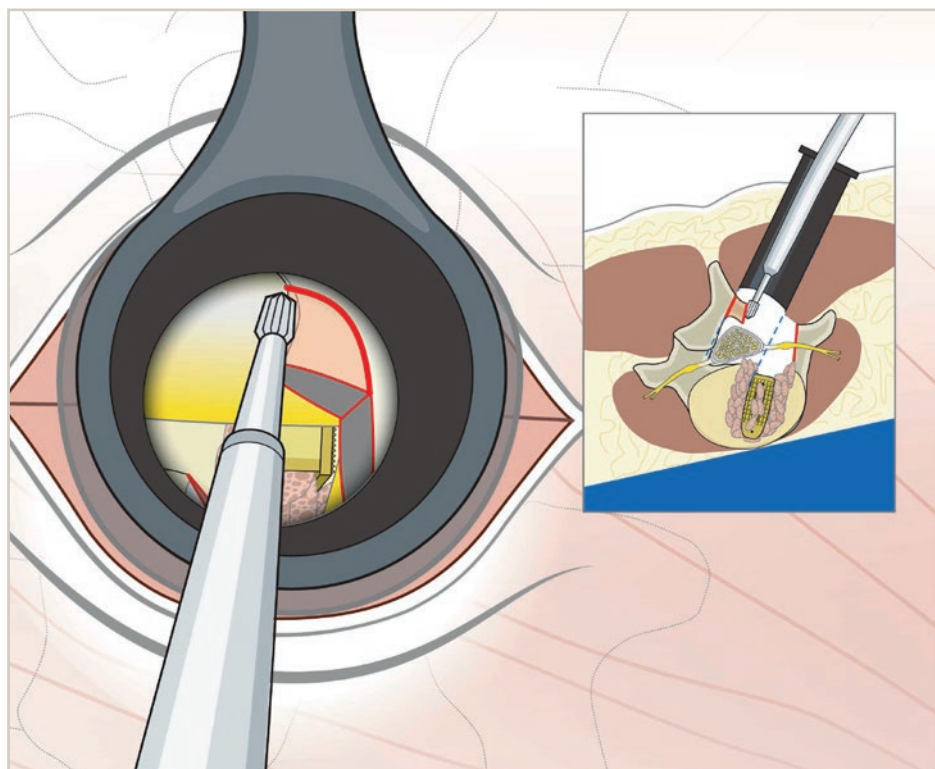
16. Additional decompression (if required)

If necessary additional decompression can be performed with the table rotated to treat more central stenosis.



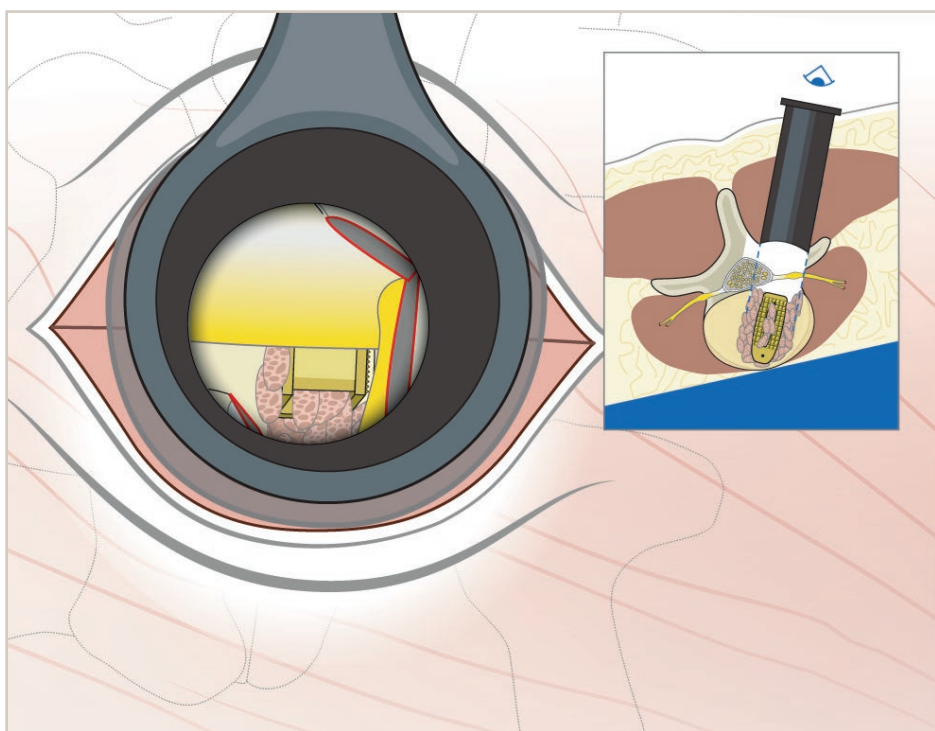
17. Removal of additional lamina

A high-speed burr can be used to remove additional lamina as far medial as the base of the spinous process.



18. Completion of all steps

Here we see the decompression, including complete laminectomy, ligamentum flavum removal, and facetectomy as accomplished through the tubular retractor.



AO Spine International
Stettbachstrasse 6
8600 Duebendorf
Switzerland

T +41 44 200 24 20
F +41 44 200 24 12
education@aospine.org
www.aospine.org