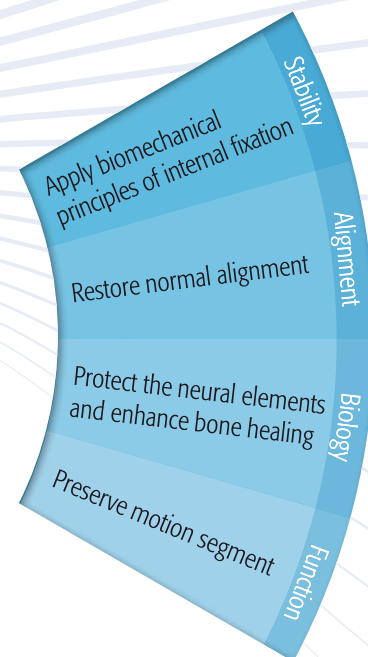


The AOSpine Principles

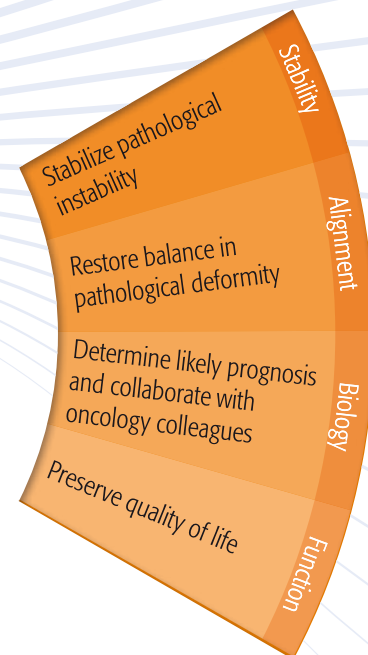

STABILITY—ALIGNMENT—BIOLOGY—FUNCTION



The four principles to be considered as the foundation for proper spinal patient management.

The AOSpine Principles

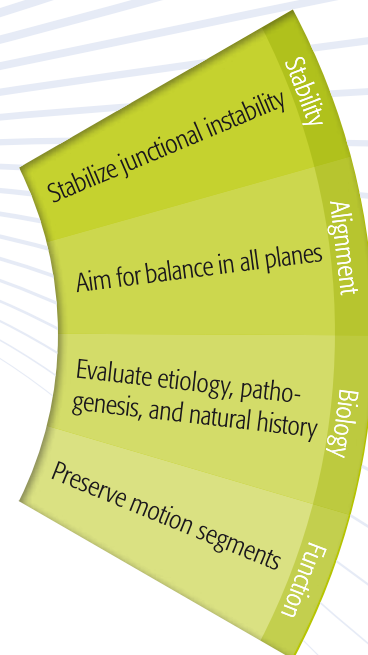
STABILITY—ALIGNMENT—BIOLOGY—FUNCTION



The four principles to be considered as the foundation for proper spinal patient management.

The AOSpine Principles

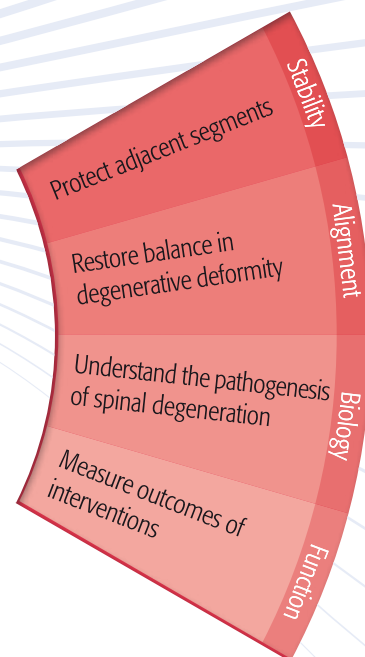
STABILITY—ALIGNMENT—BIOLOGY—FUNCTION



The four principles to be considered as the foundation for proper spinal patient management.

The AOSpine Principles

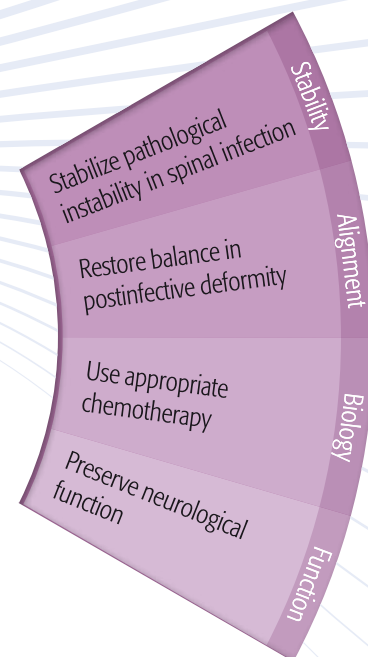
STABILITY—ALIGNMENT—BIOLOGY—FUNCTION



The four principles to be considered as the foundation for proper spinal patient management.

The AOSpine Principles

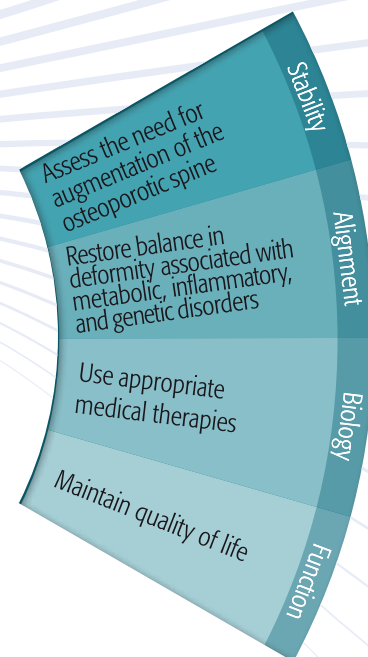
STABILITY—ALIGNMENT—BIOLOGY—FUNCTION



The four principles to be considered as the foundation for proper spinal patient management.

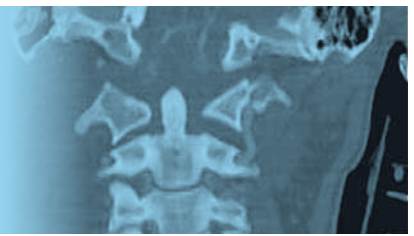
The AOSpine Principles

STABILITY—ALIGNMENT—BIOLOGY—FUNCTION



The four principles to be considered as the foundation for proper spinal patient management.

Trauma



Stability

Apply biomechanical principles of internal fixation

The biomechanical principles of internal fixation for trauma include load sharing between implants and spinal elements.

More axial load is supported by the vertebral bodies than the posterior elements. Anterior column support is necessary to protect posterior implants during bone healing. Posterior constructs are strengthened by cross-links. Anterior plate systems act as a tension band in extension and a buttress in flexion.

Alignment

Restore normal alignment

Normal spinal alignment balances the head and thorax over the lower limbs. In the sagittal plane the gravity line of the center of body mass passes through the junctional regions of the spine, then through the femoral heads. In the coronal plane the head is centered over the sacrum. Correction of malalignment following trauma is essential for optimal spinal function.

Biology

Protect the neural elements and enhance bone healing

Protection of the spinal cord and spinal nerves following trauma is paramount. Maintenance of adequate oxygenation and perfusion of the cord is essential during initial resuscitation. In the presence of neurological deficit, early reduction of displacements and decompression of neural structures may improve neurological recovery. Bone healing is vital for maintenance of spinal alignment, stability, and function. Augmentation with bone grafts, bone growth factors, or vertebroplasty may be required.

Function

Preserve motion segments

Early mobilization after spinal trauma minimizes the risks of recumbency. Spinal trauma implants must be able to resist the stresses of spinal loading during bone healing or be protected by external supports. Long-segment constructs resist deformity but sacrifice motion at normal levels. Short-segment fixation is preferred in the lumbar region to maintain motion segments.



Tumor

Stability

Stabilize pathological instability

Spinal instability due to primary or secondary malignant disease may arise out of destruction of the spine by the tumor or following surgical resection. Stabilization may require internal fixation, anterior column reconstruction, and posterior fusion. Anterior or posterior, or combined approaches may be needed. Long constructs offer greater stability. Vertebral body reconstruction with biological implants is preferred if the prognosis is greater than 12 months. Artificial devices or PMMA may be used in palliative surgery.

Biology

Determine likely prognosis and collaborate with oncology colleagues

Management of malignant spinal disease is usually undertaken by collaboration between surgeons, medical oncologists, radiation oncologists, and interventional radiologists. The choice of optimal treatment depends on the nature of the tumor and the likely prognosis. In primary tumors, surgical resection for cure usually requires clear margins. For metastatic disease, surgical treatment may be for pain relief, neural decompression, or debulking, and occasionally for excision of isolated metastases in suitable tumors.

Alignment

Restore balance in pathological deformity

Collapse of the spine due to malignant disease typically results in a spinal deformity, which in turn may produce neurological compression. Restoration of normal alignment, combined with decompression, often requires complex reconstructions. The likely prognosis determines whether realignment should be undertaken.

Function

Preserve quality of life

Preserving spinal function and minimizing disability must be considered in the context of maintaining quality of life in malignant spinal disease. In all cases the potential morbidity associated with surgical intervention must be balanced against the likely prognosis.



Deformity

Stability

Stabilize junctional instability

Deformities of the craniocervical or lumbosacral junction may be unstable. Stabilization of the craniocervical junction often requires occipitocervical fixation, with or without decompression of the spinal cord. Lumbosacral spondylolisthesis may be stabilized in situ or reduction can be performed, either partial or complete.

Alignment

Aim for balance in all planes

Spinal imbalance in coronal and sagittal plane deformities is common. During corrective surgery for scoliosis, kyphosis, and spondylolisthesis the goal is often to correct the deformity as much as possible, but restoration of balance does not necessarily involve complete correction of all deformities. In some cases it may be better to partially correct the deformity in order to maintain balance in all planes.

Biology

Evaluate etiology, pathogenesis, natural history

The underlying cause and specific pathogenesis of each spinal deformity determines the natural history of the condition. Surgical interventions with their potential risks need to be balanced against the likelihood of improving the natural history, such as avoiding future complications of the untreated condition.

Function

Preserve motion segments

Long spinal fusions for deformity correction are often necessary and frequently involve extension into the lumbar spine or sacropelvic area, sacrificing motion segments. Adequate preoperative planning and consideration of anterior instrumentation can often preserve levels for future mobility.



Degeneration

Stability

Protect adjacent segments

The goal of fusion for painful segmental degeneration of the spine is to relieve pain and restore function by achieving a solid arthrodesis of the selected motion segments. Fusion can be enhanced by the addition of internal fixation. Concerns about the long-term effect of spinal arthrodesis on the adjacent mobile segments have led to the development of many nonfusion interventions with the aim of achieving pain reduction and functional improvement without sacrificing mobility.

Biology

Understand the pathogenesis of spinal degeneration

Although spinal degeneration is a natural aging process, many patients develop disabilities due to pain, loss of function, or compressive neurological syndromes. For therapeutic interventions aimed at relieving pain, restoring function, or decompressing neural elements the possibility of future progression of degeneration at treated and untreated levels must also be considered. Future biological interventions, such as stem cell implants or biomechanically active implants, may not be possible if previous surgical interventions preclude their use when they become available.

Alignment

Restore balance in degenerative deformity

Degenerative scoliosis, kyphosis, and spondylolisthesis often result in spinal imbalance. Particularly in the elderly, imbalance of the sagittal plane is not well tolerated. The goal of corrective surgery for degenerative deformity should be to restore alignment and balance. In the lumbar spine this usually requires long fusions extending into the thoracic region above and the lumbosacral junction below in order to avoid decompensation if the fusion is too short.

Function

Measure outcomes of interventions

Functional outcome tools that measure the benefits and costs of therapeutic interventions for spinal degeneration are essential to allow surgeons, physicians, patients, and funding bodies to assess their efficacy.



Infection

Stability

Stabilize pathological instability in spinal infection

Instability of the spine following infection can result from the destruction of bone by the infective process or following surgical debridement or decompression. Reconstruction with interbody grafts or cages and rigid internal fixation is required. Current evidence suggests that the addition of internal fixation does not increase the likelihood of recurrence of infection.

Alignment

Restore balance in postinfective deformity

The typical deformity following infection of the spine is a localized kyphosis due to loss of vertebral body integrity. While the local deformity may be significant, overall spinal balance is usually maintained. However, realignment of the spine may be required for deformities that threaten to compromise the spinal cord.

Biology

Use appropriate chemotherapy

Confirmation of the causative organism in spinal infection is best obtained by CT biopsy. Appropriate antibacterial or antituberculous chemotherapy is the mainstay of treating spinal infection. Duration of treatment is determined by the nature of the infection and the condition of the patient.

Function

Preserve neurological function

The presence of neurological compromise by extension of an abscess into the epidural space or kyphotic compression requires surgical decompression, with or without reconstruction and stabilization.



Metabolic, Inflammatory, Genetic

Stability

Assess the need for augmentation of the osteoporotic spine

Normal cancellous bone of a vertebral body makes up about 15% of the volume of the vertebra. Bone density decreases with age. In the osteoporotic spine, medical and surgical augmentation may be required to treat fragility fractures or prepare the vertebral body for surgical implants.

Biology

Use appropriate medical therapies

Calcium content of bone is influenced by age, sex, diet, sunlight exposure, hormones, physical activity, and comorbidities. Treatment of osteoporosis is a major public health issue. The cost of disability related to fractures is reduced by use of appropriate medical therapies.

Alignment

Restore balance in deformity associated with metabolic, inflammatory, and genetic disorders

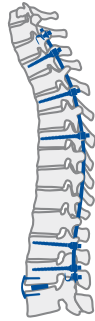Deformity arising from osteoporotic collapse of the spine or inflammatory conditions such as rheumatoid arthritis and ankylosing spondylitis can result in loss of spinal balance. Corrective surgery requires an understanding of the specific features of the underlying condition to ensure enduring restoration of spinal alignment.

Function

Maintain quality of life

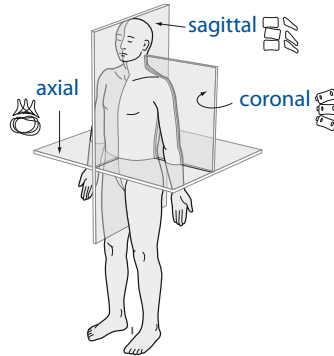
Patients with osteoporotic spinal fractures or longstanding inflammatory spondyloarthropathies are often elderly and frail. Therapeutic interventions must balance the desire for improved function against the possible loss of quality of life due to the development of complications.

The AOSpine Principles



Stability

Stabilization to achieve a specific therapeutic outcome

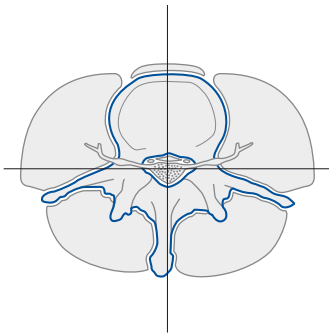


Alignment

Balancing the spine in three dimensions

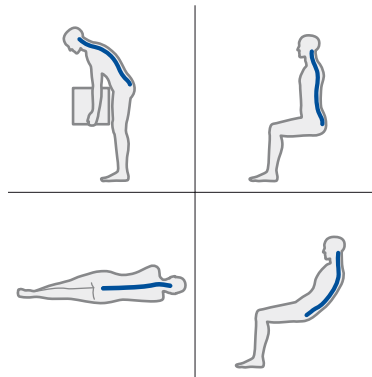
Biology

Etiology, pathogenesis, neural protection, and tissue healing



Function

Preservation and restoration of function to prevent disability



The four principles to be considered as the foundation for proper spinal patient management.